VOLUME 103 • NUMBER 1 • JANUARY 1999

AMERICAN SOCIETY OF
PLASTIC AND RECONSTRUCTIVE
SURGEONS, INC.

CME
Expanded
Cosmetic Section

Plastic and Reconstructive Surgery®

Journal of the American Society of Plastic and Reconstructive Surgeons, Inc.
Official Organ of the American Association of Plastic Surgeons
Official Organ of the American Society for Aesthetic Plastic Surgery, Inc.
Official Organ of the American Society of Maxillofacial Surgeons

Anatomic Basis and Clinical Implications for Nasal Tip Support in Open versus Closed Rhinoplasty

William P. Adams, Jr., M.D. Rod J. Rohrich, M.D., Larry H. Hollier, M.D., John Minoli, M.D., Lee K. Thornton, M.D., and Ildiko Gyimesi, M.D.

Dallas, Texas

Successful rhinoplasty depends on nasal tip support and its influence on nasal tip projection. The factors involved in nasal tip support are numerous; however, the role of the anterior septum versus the lower lateral cartilages has been debated in the literature. The purpose of this study was to quantitate, using fresh cadavers, the critical elements for nasal tip support with open versus closed rhinoplasty techniques.

Multiple nasal manipulations, including cephalic trim, cephalic trim and interruption of the lower lateral cartilages, dorsal hump resection (1 to 4 mm), submucous resection of the septum, and complete septal removal, were performed using fresh cadaver heads and using both the open and closed rhinoplasty approach. Changes in nasal tip support were recorded.

In comparing similar procedures, the mean loss of tip projection for the open approach was 3.43 mm versus 1.98 mm for the closed approach ($p < 0.001$). There was a significantly larger loss of tip projection in open versus closed procedures for cephalic trim, cephalic trim and interruption of the lower lateral cartilages, and cephalic trim with interruption of the lower lateral cartilages and septum removal ($p < 0.001$, 0.001, and 0.001, respectively). We attributed the differences between the open and closed approaches to the increases in ligamentous disruption and skin undermining that occur when using the open approach. Septum manipulation in general resulted in larger losses in tip support in both the open and closed approach.

We conclude that the open approach for rhinoplasty results in a significantly increased loss of tip projection when compared with the closed technique due to the larger disruption of ligamentous support. Contrary to previous data, septal manipulation resulted in significant losses of tip projection, most likely secondary to lowering the nasal septal angle, and this effect may be more significant in closed rhinoplasty. The apparent clinical implications are that active measures, such as columellar struts and/or suture techniques for adding or maintaining nasal tip support during rhinoplasty, are indicated, especially when using the open approach and when any anterior septal alteration is performed using the open or endonasal approach. (*Plast. Reconstr. Surg.* 103: 255, 1999.)

Successful rhinoplasty depends on nasal tip support and its influence on nasal tip projection. However, the primary components of nasal tip support have been debated for many years. The open approach was popularized by Goodman[1] in the 1970s, and its increasing use and improved exposure result in an increased chance of alteration of structures contributing to tip support. Thus, fully comprehending nasal tip support is essential to the rhinoplasty surgeon seeking reproducible results during open and closed rhinoplasty.

In 1971, Janeke and Wright[2] examined the structural support of the nasal tip through multiple cadaver dissections. They concluded that the components of nasal tip support included the fibrous connections between the upper and lower lateral cartilages, structural support extending from the lateral crus to the pyriform aperture, the interdomal ligaments between the paired domes of the lower lateral cartilages, and the medial crural attachment of the caudal septum (Fig. 1). Subsequent reports have further considered the anatomic components of nasal tip support and its influence on nasal tip projection; however, conclusions from these studies have not been homogeneous and have not been reproducible.[3–6] Al-

From the Department of Plastic and Reconstructive Surgery at University of Texas Southwestern Medical Center. Received for publication September 16, 1998.

Presented at the Annual Meeting of the American Society of Plastic and Reconstructive Surgeons, in San Francisco, California, September 21 through 24, 1997.

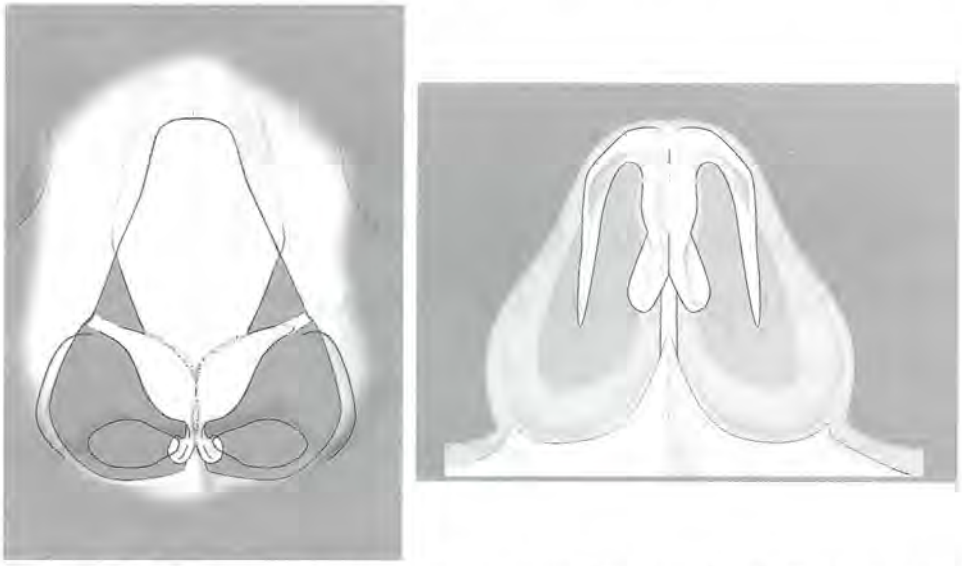

FIG. 1. The fibrous connections between the upper and lower lateral cartilages, the structural support extending from the lateral crus to the pyriform aperture, the interdomal ligaments between the paired domes of the lower lateral cartilages, and the medial crural attachment of the caudal septum are depicted.

though the lower lateral cartilages have been primarily implicated in tip support, the relative role of the septum has yet to be fully elucidated. Furthermore, Peck[7] has advocated the primary role and importance of the anterior septum to maintain projection.

Although these authors have suggested different elements as the primary factors for nasal tip support, little quantitative data exists. There is no one element (lower lateral cartilages, septum, or ligaments) that is more important than the others for nasal tip support and, ultimately, maintaining nasal tip projection; however, it would be very helpful to the rhinoplasty surgeon to have a basic idea of the relative contributions of both the structural nasal components, such as the septum and lower lateral cartilages, and the many ligamentous elements of nasal tip support.

The purpose of this study was to quantitate, using fresh cadaver heads, the critical elements of nasal tip support using several commonly performed procedures during open and closed rhinoplasty. Recommendations and conclusions based on these data are formulated.

MATERIALS AND METHODS

An initial pilot study was performed on 60 cadaver heads, which confirmed the feasibility of this project.[8] After this preliminary feasibility study, a refined protocol was developed, and 75 fresh cadaver heads were analyzed in detail (Table I). Nasal tip projection was defined as a perpendicular measurement from the tip-defining points to the posterior point of the nasal-cheek junction at the alar base (Fig. 2). The fresh cadaver heads were obtained from the University of Texas Southwestern Medical Center at Dallas, Anatomy Department. The various rhinoplasty techniques, using either a closed or an open approach, were recorded (Table I).

Assessment of Changes in Nasal Tip Projection

All fresh cadaver heads had nasal tip projection measured and recorded before any manipulation and, then, after each subsequent technique. In each open case, the nasal skin was

TABLE I

Techniques Performed for the Closed or Open Approach

Closed (n = 52)	Open (n = 54)
Cephalic trim (11)	Open approach (incisions only) (6)
Cephalic trim, interruption of the LLC (11)	Cephalic trim (18)
Cephalic trim, interruption of the LLC, remove septum (11)	Cephalic trim, interruption of the LLC (5)
Remove septum (19)	Cephalic trim, interruption of the LLC, remove septum (5)
	Remove septum (10)
	Rasp dorsum 1 mm (3)
	Take down dorsum 3 to 4 mm (3)
	Submucous resection (4)

LLC, lower lateral cartilages.

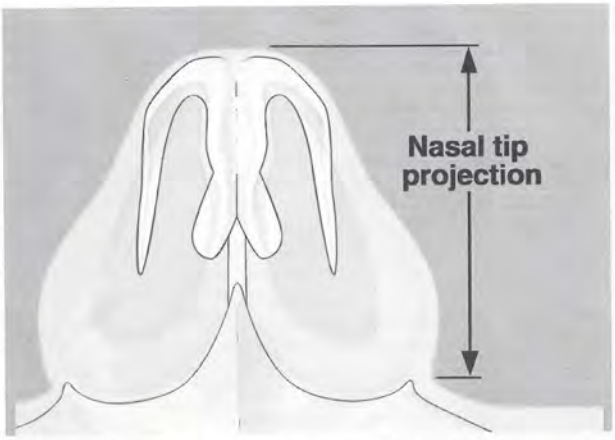

FIG. 2. Nasal tip projection was defined as a measurement from the tip-defining points to the posterior point of the nasal-cheek junction at the alar base.

redraped back to its appropriate position before remeasurement of nasal tip projection.

Open Rhinoplasty Technique

The open rhinoplasty approach used a standard transcolumellar stair-step and marginal intracartilaginous incisions to allow full exposure of the nasal endoskeleton. The changes in tip projection for the "open approach only" incisions were recorded.

Cephalic Trim

Closed and open cephalic trim, leaving 6-mm caudal rim strips (Fig. 3), were performed using intracartilaginous incisions for the closed approach and as described in the previous section for the open approach.

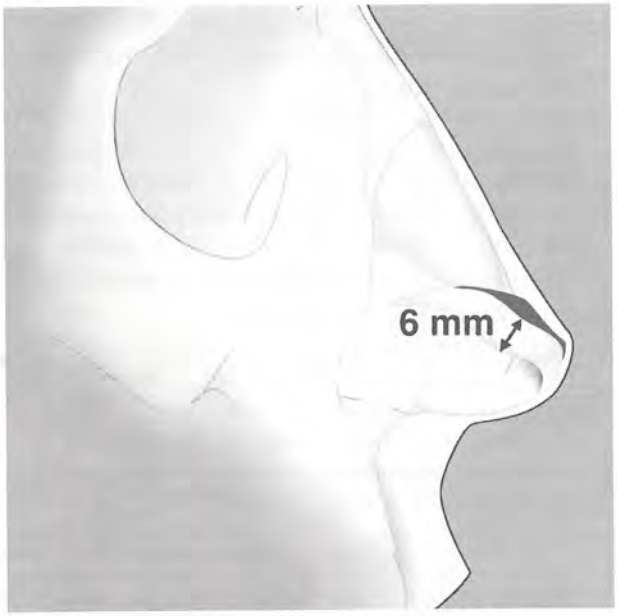

FIG. 3. Cephalic trim leaving a 6-mm caudal rim strip.

Cephalic Trim and Interruption of the Lower Lateral Cartilages

The closed cephalic trim and interruption of the lower lateral cartilages (Fig. 4) were performed through an intracartilaginous intranasal incision. A 6-mm rim strip was left for the cephalic trim. The interruption of the lower lateral cartilages was performed 3 to 4 mm lateral to the alar dome. The same procedure was performed using the open approach.

Septum Removal

The closed removal of the septum was performed through a hemitransfixion incision. The entire septum, including the entire quadrangular cartilage and part of the perpendicular plate of the ethmoid, was removed submucoperichondrially using this approach (Fig. 5). The open septum removal was performed through our standard open approach, exposing the septum in the midline near the ante-

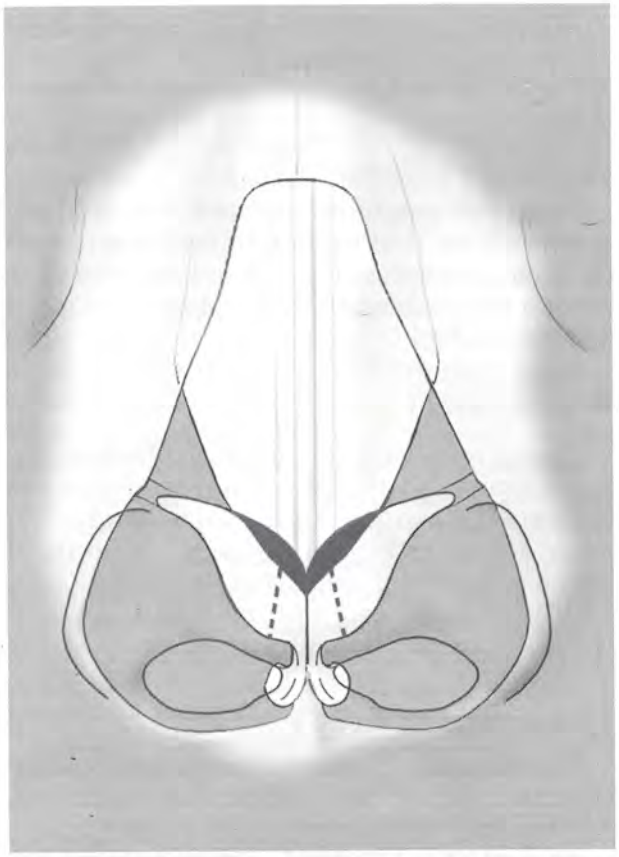

FIG. 4. Cephalic trim and interruption of the lower lateral cartilages were performed using both the closed and open approach. A 6-mm rim strip was left for the cephalic trim. The interruption of the lower lateral cartilages was performed 3 to 4 mm lateral to the alar dome.

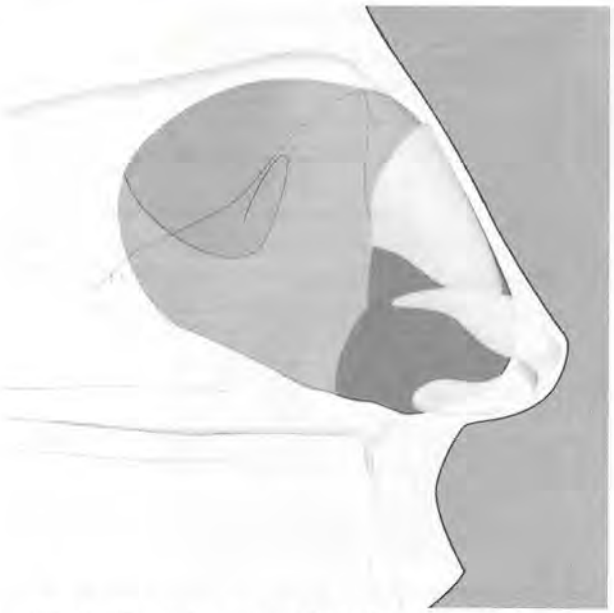

FIG. 5. The entire septum, including the entire quadrangular cartilage and part of the perpendicular plate of the ethmoid, was removed submucoperichondrially using this approach.

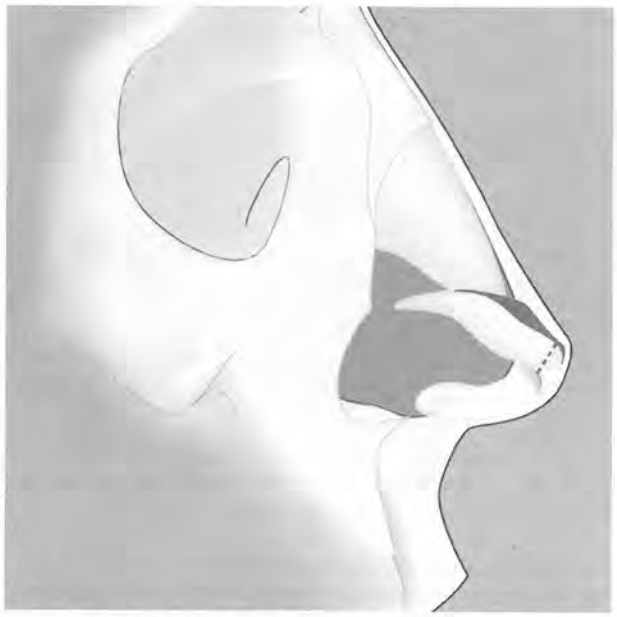

FIG. 6. Cephalic trim, interruption of the lower lateral cartilages, and septum removal were performed using both the closed and open approach.

rior septal angle by developing submucoperichondrial planes bilaterally.

Cephalic Trim with Interruption of Lower Lateral Cartilages and Septum Removal

Using the previously described techniques, cephalic trim, interruption of the lower lateral cartilages, and complete septum removal were accomplished using both the closed and open approach (Fig. 6).

Dorsal Reduction

Dorsal reduction was performed using the open approach only. The 1-mm reduction was accomplished with a Forman nasal rasp. The 4-mm dorsal reduction was again performed with a rasp for the bony nasal bones, and a no. 11 blade for reduction of the dorsal aspect of the quadrangular septal cartilage.

Open Submucous Resection

Using the open approach, a standard submucous resection of the septum was performed, leaving 1-cm dorsal and caudal struts.

All data were recorded, and subsequent statistical analysis was done through the University of Texas Southwestern Medical School at Dallas, Biostatistical Department, using the Mann-Whitney U test (R.R.).

RESULTS

The results for all approaches and techniques are summarized in Table II. Overall, comparing all techniques for the closed approach ($n = 52$) to the similar manipulations for the open approach ($n = 38$), a significantly larger loss in tip projection was observed using the open approach (mean, 3.43 ± 2.46 mm) versus the closed approach (mean, 1.98 ± 1.89 mm) (Mann-Whitney U test, $p < 0.001$). No loss in tip projection was seen when using the standard incisions for the open approach and exposing the nasal endoskeleton (Table II).

Significant differences between the closed versus open techniques were found for cephalic trim ($p < 0.001$), cephalic trim with interruption of the lower lateral cartilages ($p < 0.001$), and cephalic trim with interruption of the lower lateral cartilages and septum removal ($p < 0.001$) (Table III). Similar losses in tip projection were seen for septum removal comparing the closed versus open techniques ($p = 0.735$) (Table III).

The 1-mm dorsal reduction resulted in no loss of tip projection; the 4-mm dorsal reduction resulted in an average of 3.3 mm of projection loss; and the submucous resection lost an average of 1.5 mm (Table II).

DISCUSSION

Modification of the intricate relationships of the nose may result in unpredictable results

TABLE II

Results of Each Technique with the Closed versus Open Approach

Approach	Technique	Number	Average Loss of Projection	Range
Closed*	Cephalic trim	11	0	0
Closed*	Cephalic trim, interruption of LLC	11	0 mm	0 mm
Closed*	Cephalic trim, interruption of LLC, remove septum	11	2.5 mm	1–5 mm
Closed*	Remove septum	19	3.9 mm	0–10 mm
Open	Open only	6	0	0
Open*	Cephalic trim	18	2.3 mm	1–4 mm
Open*	Cephalic trim, interruption of LLC	5	3.3 mm	3–4 mm
Open*	Cephalic trim, interruption of LLC, remove septum	5	7.3 mm	6–9 mm
Open*	Remove septum	10	3.6 mm	2–7 mm
Open	Rasp dorsum 1 mm	3	0	0
Open	Take down dorsum 3–4 mm	3	3.33	3–4
Open	SMR	4	1.5	0–2

* Closed versus open techniques, $p < 0.001$, Mann-Whitney U test.
LLC, lower lateral cartilages; SMR, submucous resection of the septum.

during aesthetic rhinoplasty. Detailed knowledge of these components, particularly the tip-supporting elements of the nose, are necessary for reproducible results. Interestingly, there have been conflicting reports on what structures play the most significant role in nasal tip support and their ultimate influence on nasal tip projection.

Subsequent to Janeke and Wright's[2] initial report on the components of nasal tip support in 1971, McCollough and Manget[4] adopted a similar tripod analogy to depict nasal tip support. They described four elements of tip support: (1) the telescoping relationship between the upper and lower lateral cartilages; (2) the length, size, and direction of the lateral crura; (3) the membranous attachment between the medial crura and caudal septum; and (4) the ligamentous attachments of the anterior septum and dome of the lower lateral cartilage.

Conversely, Beekhuis and Colton[3] stated that the most important factors controlling nasal tip support are the strength of the alar cartilage and the position of the septal angle and, unlike their predecessors,[2,4] they diminished the importance of the ligamentous structures. The same authors reviewed multiple structures implicated in nasal tip support, including the membranous columella, attachments of the upper and lower lateral cartilages, the dome attachment of the lower lateral cartilages, attachments between feet of the medial crura and cartilaginous septum, attachments between the lateral crura and bone of the pyriform aperture, and the anterior nasal spine. They stated that these components do not have true structural control of the nasal tip and may be modified to a certain extent without alteration of tip projection.

Rich et al.[6] believed that nasal tip support was directly influenced by the septal angle; the medial and lateral crura of the alar cartilages; and the relationship between the medial crura, the caudal septum, the nasal spine, and the soft tissue of the lobule, among others. Petroff et al.[5] observed that the most important components of nasal tip projection in the postsurgical nasal tip are the medial crura, their attachments to the caudal septum, and the presence of additional cartilage grafts placed between the medial crura or beneath the crural feet. These authors also observed loss of tip projection after cephalic trim and domal division, which is consistent with our anatomic data.[5]

TABLE III

Comparison of the Closed versus Open Approach for Similar Techniques

Technique	p Value (Mann-Whitney U test)	Closed			Open		
		Number	Mean ± SD	Median	Number	Mean ± SD	Median
Cephalic trim	<0.001	11	0 ± N/A	0	18	2.3 ± 0.7	2
Cephalic trim, interruption of LLC	<0.001	11	0 ± N/A	0	5	3.3 ± 0.2	3
Cephalic trim, interruption of LLC, septum removal	<0.001	11	2.6 ± 1.4	2	5	7.3 ± 1.2	7
Septum removal	0.735	19	3.9 ± 2.6	4	10	3.6 ± 1.4	3.5

LLC, lower lateral cartilages; SD, standard deviation.

Our anatomic study was designed to add another variable to the nasal tip support controversy. Although prior clinical reports have surveyed some of the variables/factors that provide tip support, no study has attempted to systematically look at each technique in closed versus open rhinoplasty and to subsequently quantitate the critical elements for tip support. Our intention was to evaluate which anatomic components were important in providing nasal tip support, and we also wanted to improve our understanding of the relative importance of common surgical techniques (closed and open) on tip support. Unfortunately, this type of anatomic study has specific drawbacks that are unavoidable. Although fresh cadaver noses were used, the typical cadaver age is significantly older than most patients desiring rhinoplasty. The exact tissue responses/losses in tip projection in the cadaver or elderly nose may not correlate with the younger patient. Additionally, intrinsic to any cadaver study is the absence of wound healing, which may provide additional tip support with time, which underscores the need for initial surgeon-directed support. Nevertheless, the age and type of noses used were all similar, as were the relative differences in loss of projection. Furthermore, the use of the intracartilaginous incisions in the closed cephalic trim subgroup also makes the study less controlled because, regardless of operator experience, it is extremely difficult to accurately predict the size, location, and remaining rim-strip using this incision. If repeating this study, we would redesign the closed cephalic trim and cephalic trim with interruption of the lower lateral cartilages subgroups to be performed using the cartilage delivery technique, which is more precise. The additional open procedures (open rasp dorsum, take down of the dorsum by 3 to 4 mm, and submucous resection of the septum; Table II) were done to look at their individual effects on tip projection. Because of limitations in the supply of fresh cadaver heads, the analogous closed techniques were not performed; however, we felt this data provided useful information and allowed some comparison using our past clinical experiences. Despite some of the inherent drawbacks of a study of this type, it is impossible to perform in live patients, and we offer it as a general guide to the rhinoplasty surgeon rather than an absolute dictum. The study is further validated by our clinical experience, which correlates with this laboratory data.

We chose to leave a 6-mm rim strip for our cephalic trims in an attempt to simplify and standardize this part of the study. We acknowledge that there are various anatomic differences in the lower lateral cartilages between individuals; however, it is what one leaves behind (i.e., the 6-mm rim strip) that matters.

Our data demonstrated that the septum may play a more significant role in nasal tip support than previously reported. The strength of the lower lateral cartilage and soft-tissue attachments to this structure have been deemed a primary component in tip support in past reports[2,4,5]; however, our data indicate that the septum is equally important in maintaining tip support and projection. The importance of the septum was seen in both the closed and open approach, with greater losses in tip projection after removal of the septum using either approach (Table II). Less radical septal alterations, including 4-mm dorsal reduction and standard submucous resection, also resulted in loss of nasal tip support (Table II). Because we do not routinely see loss of tip projection clinically for closed septoplasties (submucous resection of the septum) or closed dorsal reductions, our results may be related to the amount of skin undermining in the open versus the closed approach. In our study, all the cadaver heads tended to have the anterior septal angle below the domes of the lower lateral cartilages (the most common relationship). The importance of the septum in this relationship (i.e., tension tip nose) has long been recognized; however, our data indicate its importance for tip support in the nontension tip and in the open or endonasal approach.

The open rhinoplasty approach itself did not result in a significant loss of tip projection; however, compared with the closed approach procedures, such as cephalic trim, it resulted in significant differences in nasal tip projection. This indicates that disruption of the ligamentous support between the upper and lower lateral cartilages is important for tip support, and this structure is more completely released through the open approach. Furthermore, separation of the skin from the nasal skeleton may not have an effect on tip projection alone, but it may synergize with other rhinoplasty techniques to result in a larger loss of tip projection. This may help explain some of the results in Table II, notably, that we found no loss of tip projection for either the closed cephalic trim

or the cephalic trim with interruption of the lower lateral cartilages. Not until the septum was removed was a loss in tip projection manifested. We explain these results by the degree of skin undermining (which was minimal for our closed technique). It is the combination of skin, ligaments, and cartilage that ultimately provides tip support. As the surgeon progressively disrupts more of these structures, a larger loss of tip projection is realized. Clinically, closed rasping of the dorsum does not result in loss of tip projection; however, this requires minimal skin undermining and release of supporting structures.

We conclude that loss of tip support and tip projection is more likely to occur with the open approach, and specific technical measures using suture techniques (medial crural, interdomal) and columellar struts are critical to maintain and augment long-term tip projection. This parallels the experience of the senior author (R.J.R.) in the use of the open approach. One must reconstruct the tip support, specifically the medial crura and interdomal regions. This is facilitated by the use of suture techniques and an invisible columellar strut graft between the medial crura or extension graft to unify the tip.[9] Using this philosophy, one may use autologous methods to reconstruct and support the nasal tip, providing a more natural long-term appearance. This has greatly diminished our use of visible onlay grafts in primary rhinoplasty and limits these type of grafts to the thick-skinned nose and secondary rhinoplasty cases. Furthermore, after septal reduction, especially anteriorly, one must be cautious about reducing tip projection and take similar measures, if indicated, to avoid losses in tip projection using either the open or closed rhinoplasty approach.

Rod J. Rohrich, M.D.
Department of Plastic and Reconstructive Surgery
5323 Harry Hines Blvd.
University of Texas Southwestern Medical Center
Dallas, Texas 75235

ACKNOWLEDGMENTS

We would like to thank John Shamoun, M.D., for his efforts in the initial pilot study that gave us the basis for this study. We also extend our gratitude to Debby Noble, Karalee Turner, Johnathon Young, Robert Schwartz, M.D., and Jack B. Robinson, Jr., Ph.D., for their expert assistance during the cadaver dissections. We also thank Johnathon Young, M.I., and Steven Brown, M. I., for their expertise in medical illustration and R. Risser from Biostatistics at University of Texas Southwestern Medical Center for his statistical analysis of the data. Finally, we express our gratitude to Dr. Jack Gunter for his evaluation and critique of the study.

This study was supported by the Dallas Rhinoplasty Research and Educational Fund, dedicated to the advancement of rhinoplasty.

REFERENCES

1. Gunter, J. P. The Open Approach for Rhinoplasty. In *1998 Dallas Rhinoplasty Symposium*. P. 223.
2. Janeke, J. B., and Wright, W. K. Studies on the support of the nasal tip. *Arch. Otolaryngol.* 93: 458, 1971.
3. Beekhuis, G. J., and Colton, J. J. Nasal tip support. *Arch. Otolaryngol. Head Neck Surg.* 112: 726, 1986.
4. McCollough, E. G., and Mangat, D. Systematic approach to correction of the nasal tip in rhinoplasty. *Arch. Otolaryngol.* 107: 12, 1981.
5. Petroff, M. A., McCollough, E. G., Hom, D., and Anderson, J. R. Nasal tip projection. *Arch. Otolaryngol. Head Neck Surg.* 117: 783, 1991.
6. Rich, J. S., Friedman, W. H., and Pearlman, S. J. The effects of lower lateral cartilage excision on nasal tip projection. *Arch. Otolaryngol. Head Neck Surg.* 117: 56, 1991.
7. Peck, G., Sr. Personal communication, 1994.
8. Shamoun, J., and Rohrich, R. J. Nasal Tip Support—An Anatomic Study. Presented at the Plastic Surgery Senior Residents Conference, San Diego, May 22–25, 1993.
9. Rohrich, R. J. Graduated Approach to Tip Projection in Rhinoplasty. In *The Dallas Rhinoplasty Symposium Syllabus*. 1998. P. 95.

Discussion

Anatomic Basis and Clinical Implications for Nasal Tip Support in Open versus Closed Rhinoplasty

by William P. Adams, Jr., M.D., Rod J. Rohrich, M.D., Larry H. Hollier, M.D., John Minoli, M.D., Lee K. Thornton, M.D., and Ildiko Gyimesi, M.D.

Discussion by Ronald P. Gruber, M.D.

The article by Dr. Adams and his coauthors addresses important issues in rhinoplasty. They are what are the elements that provide tip support and what elements are most important. Their study found, among other things, that the integrity of the lower lateral cartilages and the septum are two of the most important key elements. What is unique about their study, however, is that it attempts to compare differences between the open and the closed approach and their discovery that the skin itself may be a significant element in tip support.

There are a number of findings and conclusions the authors report with which I am in complete agreement. The integrity of the lower lateral cartilage attachment to the upper lateral cartilages is a key element. An intercartilaginous incision, especially when combined with a transfixion incision, often results in a profound drop in tip support—whether by the open or closed approach. That loss of tip support is best demonstrated by first palpating the tip immediately after opening the nose and palpating tip strength (Fig. 1). After the intercartilaginous and transfixion incision is made (as may be required to shorten the nose and rotate the tip), the tip is palpated once more. This is a test I perform almost routinely. The result quite often is a profound loss of tip support and strength. In fact, the combination of transfixion and intercartilagenous incisions is one of the best treatments for the overprojecting nose and can avoid the need for transection of the lower lateral cartilages and/or medial crura. The integrity of the septum is also a critical element, as anyone who has trimmed the dorsum and caudal edge of the septum in a tension-tip nose knows.

The most surprising finding of the authors' study is that the skin does seem to be a factor affecting tip projection. The authors found that simple skin elevation by itself did not result in a loss of tip projection, but it did when combined with other maneuvers. Assuming that the same amount of cephalic lower lateral crus was removed in both the open and closed techniques, one must conclude from their results that the skin is a significant factor. The only ligament visible to the naked eye between the skin and the cartilaginous framework is the dermocartilagineous ligament, which extends from the dermis to the area of the cephalic portion of the middle crura and septum. Strangely enough, Pitanguy et al.[1] reported that releasing this ligament was often necessary to provide better tip projection. Future studies need to be done to reconcile this paradox. In the meantime, the skin should be considered a potential factor causing tip projection loss, and unnecessary skin undermining (whether in the open or closed approach) should be avoided.

I do question the authors on one technical issue. From the description of the experiment, it is not clear if the skin of the columella was closed with at least one suture before measuring tip projection. Clinically, closure of the skin flap affects tip projection. In some situations when the flap is drawn towards the columellar wound and

Received for publication September 15, 1998.

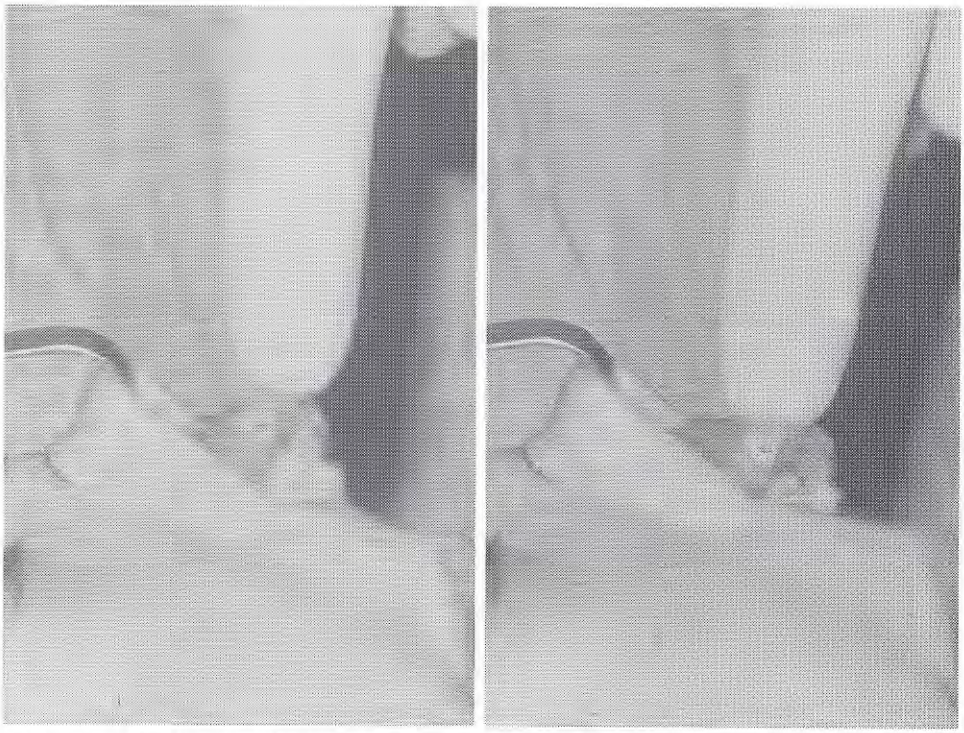

FIG. 1. After the nasal framework is exposed through the open approach, palpation of the tip reveals the tip strength support (*left*). After a transfixion incision and intercartilaginous incision, a noticeable drop in tip support is often seen. Palpation reveals the loss of tip strength support, verifying the need for suture techniques and/or invisible columellar grafts (*right*).

repaired, tip projection decreases. The exact opposite can occur if the tip cartilages are extensively mobilized. This is seen frequently when lengthening the absolutely short nose using a batten graft. In that situation, the tip cartilages are mobile because they have been separated from the caudal edge of the septum, and the skin flap is slightly foreshortened (because the nose has been lengthened). When the skin flap is closed, it actually pulls the tip cartilages anteriorly and one sees a little more projection after skin closure than before it. Whatever the role of the skin in terms of tip support proves to be, my experience concurs with the authors in that sutures and invisible grafts are outstanding, if not essential, ways to overcome the loss of support after either the open or closed approach.

What I disagree with most is when the authors say (which by no means detracts from the unique and key points made by their article), "the open approach for rhinoplasty results in a significantly increased loss of tip projection when compared with the closed technique." Closed approaches that involve tip delivery by rim incisions are very similar to the open approach in terms of the amount of skin that elevates off the nasal framework. In fact, the additional skin elevation is confined to the surface overlying the middle crura and comprises an extremely small area[2] (less than 1 × 0.5 cm). I seriously doubt if the skin attachment to the middle/medial crura provides any significant tip support, and I am confident that the authors, particularly the senior author, Dr. Rohrich, would agree with me that the price of precise cartilaginous sculpting is well worth that additional bit of undermining.

I do believe, as the authors acknowledged, that it would have been ideal to compare the open approach to the closed approach in which the tip cartilages are delivered with the aid of rim incisions. That would be the only fair comparison between the open and closed approaches. Under these circumstances, I suspect there would be absolutely no difference between the open and closed approaches. Besides, comparing a closed cephalic lower lateral crus resection to an open cephalic lateral crus resection does not have much meaning if one is not likely to perform the latter operation. It is very unlikely that I would elect to do an open approach simply to resect the cephalic portion of the lower lateral cartilages.

I do believe that the authors' results support

the contention that the least amount of soft-tissue release that can be done to accomplish the goal of precise framework sculpting is the goal we should be achieving. Sheen and Sheen[3] for example, recommend minimizing the length of the transfixion incision and not making it a routine part of skeletonization. The authors' experimental results clearly verify the principle of minimum dissection. In summary, Dr. Adams and his coauthors have carefully quantified a few elements (septal and lower lateral cartilage integrity) that have long been suspected to be key ingredients in maintaining tip projection. In addition, they shed light on the mechanisms of tip support by providing evidence that skin undermining per se (whether by the open or closed approach) can be detrimental to tip projection. Whatever technique is chosen, they remind us that suture techniques and invisible columellar grafts are an excellent means of restoring tip strength and projection.

Ronald P. Gruber, M.D.
Stanford University
3318 Elm St.
Oakland, Calif. 94609

REFERENCES

1. Pitanguy, I., Salgado, F., Radwanski, H. N., and Bushkin, S. C. The surgical importance of the dermocartilaginous ligament of the nose. *Plast. Reconstr. Surg.* 95: 790, 1995.
2. Gruber, R. P., and Peck, G. C. *Rhinoplasty: State of the Art.* St. Louis: Mosby, 1993. P. 62.
3. Sheen, J. H., and Sheen, A. *Aesthetic Rhinoplasty.* St. Louis: Mosby, 1978. P. 232.