VOLUME 99 • NUMBER 5 • APRIL 1997

PLASTIC AND RECONSTRUCTIVE SURGERY®

AMERICAN SOCIETY OF
PLASTIC AND RECONSTRUCTIVE
SURGEONS, INC.

Journal of the American Society of Plastic and Reconstructive Surgeons, Inc.
Official Organ of the American Association of Plastic Surgeons
Official Organ of the American Society for Aesthetic Plastic Surgery, Inc.
Official Organ of the American Society of Maxillofacial Surgeons

Special Topic

Diagnostic Nasal Endoscopy

Patrick H. Pownell, M.D., John J. Minoli, M.D., and Rod J. Rohrich, M.D.

New York, N.Y., and Dallas, Texas

Nasal endoscopy has revolutionized the diagnosis and treatment of nasal airway complaints.[1–26] With the endoscope, the surgeon gains the capacity for precise anatomic identification and angled, illuminated, magnified viewing of the internal nose preoperatively, intraoperatively, and postoperatively. In the office setting, the endoscope accesses and visually enhances otherwise elusive causes of nasal airway complaints. As an added benefit, an attached camera can provide a photographic demonstration to the patient or create documentation for the permanent record. The purpose of this paper is to educate and encourage practitioners of nasal surgery to improve their diagnostic abilities by incorporating endoscopy into their practice. Table I represents the considerations involved in the differential diagnosis of nasal impairment and obstruction.[10,27–31]

Historical Perspectives in Nasal Endoscopy

The use of the endoscope within the nose is not new. The first significant applications occurred at the beginning of the twentieth century when Hirschmann (1901), Reichert (1902), Valentin (1903), and Sargnon (1908) each used a modified cystoscope both to examine internal nasal anatomy and to aid in treatment of minor pathology such as nasal cysts and nasal foreign bodies.[6] By the 1920s, Spielberg and Maltz were reporting more extended use of nasal and paranasal endoscopy.[6,11]

The modern flourish in rhinologic endoscopy was triggered in the 1960s partly because of the advent of Hopkins' improved, rod-based rigid telescopes but also due to the vital studies of the German surgeon Messerklinger, who demonstrated normal and abnormal patterns of mucociliary clearance in the nose and paranasal sinuses, proposed extirpative treatment for chronic sinusitis at the confluent site of drainage (within the infundibulum of the middle meatus along the lateral nasal wall), and simultaneously incorporated the rigid telescope as the technologic foundation for diagnosis and treatment.[12–16]

During the 1970s, variations in nasal endoscopy were forwarded by the Austrian surgeon Wigand, but it is only within the last decade or so that the merit of Messerklinger's work has been universally understood and widely applied, championed by the lucid presentations of Stammberger in Europe and Kennedy in the United States.[7,8,21,22,25,26]

Furthermore, Messerklinger's contribution has been the germinal seed for broader applications of nasal endoscopy. Today it is used as a central component in the diagnosis and treatment of intranasal cerebrospinal fluid leak, nasal-orbital trauma, exophthalmos, nasoseptal deformity, epistaxis, nasal foreign body, nasolacrimal duct dysfunction, turbinate hypertrophy, postoperative nasal synechia, and adenoid surgery.[3]

Rationale for Diagnostic Nasal Endoscopy

The application of diagnostic nasal endoscopy in the office setting is an evolving issue. Clearly, the use of the endoscope is expanding, but its use must be justified. The traditional anterior rhinoscopic examination, even in the decongested state, typically provides visualization of the septum and the anterior aspect of the middle and inferior turbinates as well as an occasional limited glimpse of the middle meatus and osteomeatal complex. The endoscope clearly offers a more comprehensive view of the internal nasal anatomy.[2,9,10]

Levine[9] reported that nasal pathology in 39 percent of patients was not identified with tra-

From the Department of Plastic Surgery at the University of Texas Southwestern Medical Center, Dallas, Texas, and from private practice in New York. Received for publication October 8, 1996.

TABLE I
Differential Diagnosis of Nasal Impairment/Obstruction[10,27–31]

	Etiologies		Etiologies
Allergic	Seasonal	Mechanical	Nasal vestibule:
	Perennial		Nasal valve collapse
			Nasal valve stenosis
Congenital	Nasal encephalocele		Synechiae
	Nasal glioma		Nasal septum:
	Teratoma		Septal abscess
			Septal deviation
Endocrine	Adrenal deficiency		Septal perforation/ hematoma
	Hypothyroidism		Lateral nasal wall:
	Menstruation		Turbinate hypertrophy
	Pregnancy		Concha bullosa
Environmental	Foreign body		Nasopharynx
	Hot/dry air		Adenoid hypertrophy
	Occupational irritants		Choanal atresia
Idiopathic	Necrotizing sialometaplasia	Medicinal	Rhinitis medicamentosa (from prolonged use of OTC topical decongestants)
	Polymorphic reticulosis (lethal midline granuloma)		Systemic medicines (e.g., contraceptive hormonal therapy)
	Pyogenic granuloma		
	Sarcoidosis		
Infectious	Acute bacterial	Neoplastic	Benign
	Chronic bacterial		Malignant
	Fungal		
	Mycobacterial	Physiologic	Emotional hyperreactivity
	Parasitic/protozoal		Nasal cycle
	Spirochetal		Parasympathetic dominance (autonomic imbalance)
	Viral		
Inflammatory	Eosinophilic	Systemic	Connective tissue disorders
	Nasal polyposis		Hematopoietic disorders

ditional anterior and posterior rhinoscopic examination. Missed pathology includes acute and chronic inflammation within the middle meatus, nasal polyposis (Fig. 1), and nasal synechiae (Fig. 2). These processes are common endoscopic findings typically stemming from infectious, irritative, or traumatic causes. Many of Levine's patients had seen a number of physicians and had not received appropriate treatment prior to endoscopic investigation. In another study evaluating the importance of nasal endoscopy, Vining et al.[24] found that of 100 consecutive patients with persistent nasal complaints, as many as 9 percent of the group had an abnormal endoscopic examination in the context of negative CT radiographs. Levine's and Vining's studies clearly support the expanding role of diagnostic nasal endoscopy.

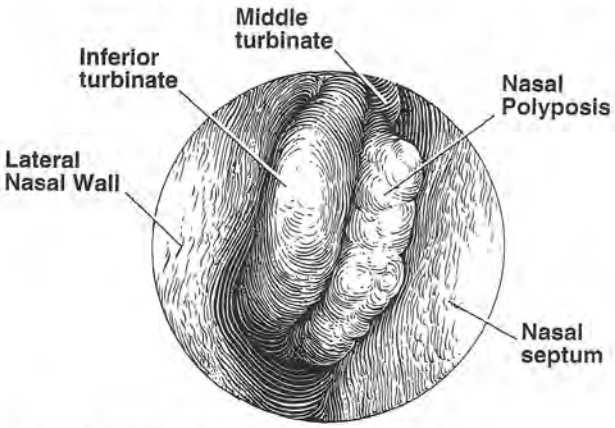

FIG. 1. Schematic view of nasal polyposis.

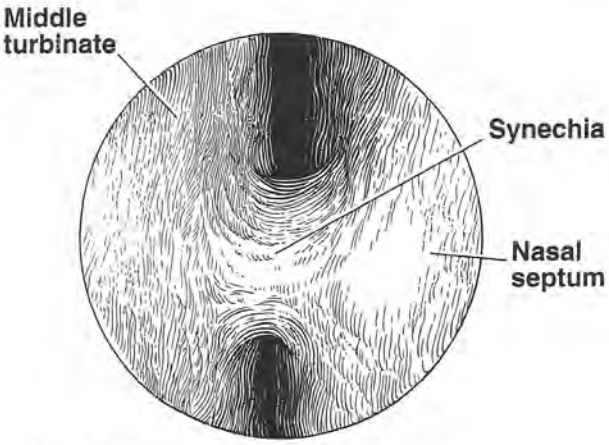

FIG. 2. Schematic view of a nasal synechia.

INTERNAL NASAL ANATOMY

The *medial nasal wall* is composed of the mucosal lined cartilaginous and bony septum and serves as a partition of the right and left nasal airways (Fig. 3). Although it is a midline structure, when it deviates in a clinically signif-

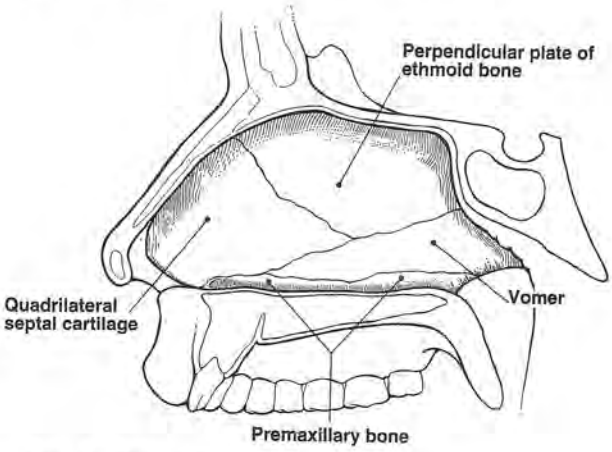

FIG. 3. The medial nasal wall.

icant way, it tends to do so at the various fusion sites of its multiple components.

The cartilaginous septum (the quadrilateral cartilage) is positioned anterosuperiorly and articulates with the upper and lower lateral cartilages and nasal bones, adding shape and support to the nasal dorsum, tip, and columella; it also abuts the three osseous elements of the bony septum along its posteroinferior edge.

The bony septum is composed of the premaxillary crest, the vomer, and the perpendicular plate of the ethmoid bone. The premaxillary crest is a thickened bone that arises from the midline fusion of the palatine processes; it is situated anteroinferiorly and serves as a trough for the quadrilateral cartilage. The vomerine bone completes the inferior support of the septum further posteriorly, coursing all the way to the sphenoid bone. Finally, the perpendicular plate of ethmoid gives rise to the posterosuperior aspect of the septum, articulating along its cephalic edge with the cribriform plate of the anterior cranial fossa and along its anterior edge with the posterior rim of the quadrilateral cartilage.

The *lateral nasal wall* is more complex (Fig. 4). In simple terms, it partitions the nasal cavity from the maxillary sinus, the ethmoid sinuses, the orbit, and the anterior cranial fossa (Fig. 5). The complex configuration of the lateral nasal wall contains the turbinate bones, which serve as protective eaves for several underlying meatal crevices. These crevices harbor multiple ostia that are channels of egress from the paranasal sinuses and the lacrimal drainage system.

The inferior turbinate is the largest and most caudal of the projecting conchal bones. It is also the most sensitive to vasoactive hypertrophy and, consequently, a frequent cause of airway obstruction.[17,18] It shields the nasolacrimal duct, which empties beneath, along the lateral nasal wall. The nasolacrimal ostium is seldom a site of disease. Rather, the cephalic course of the duct is more prone to trauma, infection, and idiopathic dysfunction, occasionally necessitating dacryocystorhinostomy.[2]

Of special interest to the endoscopist, the middle turbinate and its adjacent ostial system within the middle meatus serve as the point of confluent drainage from the frontal, maxillary, and anterior ethmoid sinuses. This underlying meatal area has been described clinically and radiographically as the *osteomeatal unit* or the *osteomeatal complex* (Fig. 6). As such, it represents the crossroads of the draining sinuses

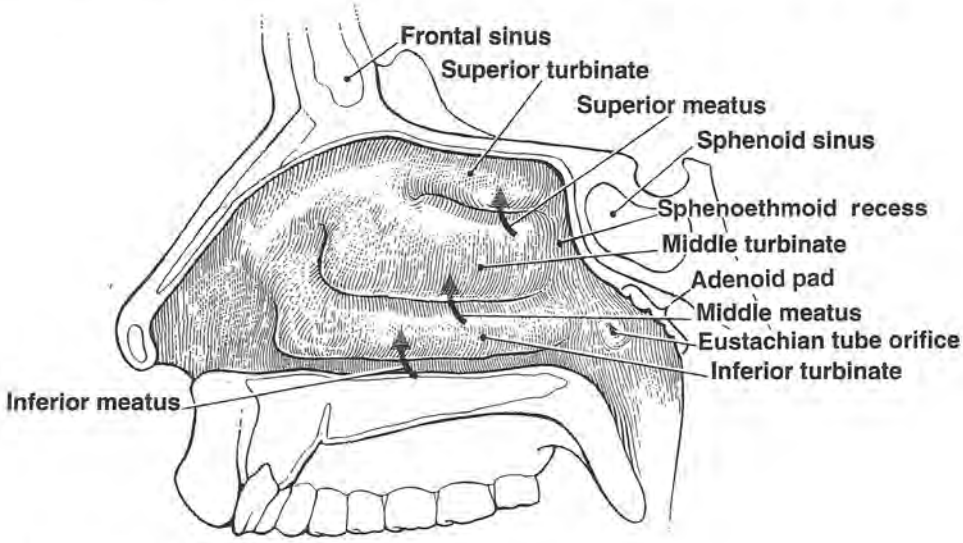

FIG. 4. The lateral nasal wall and nasopharynx.

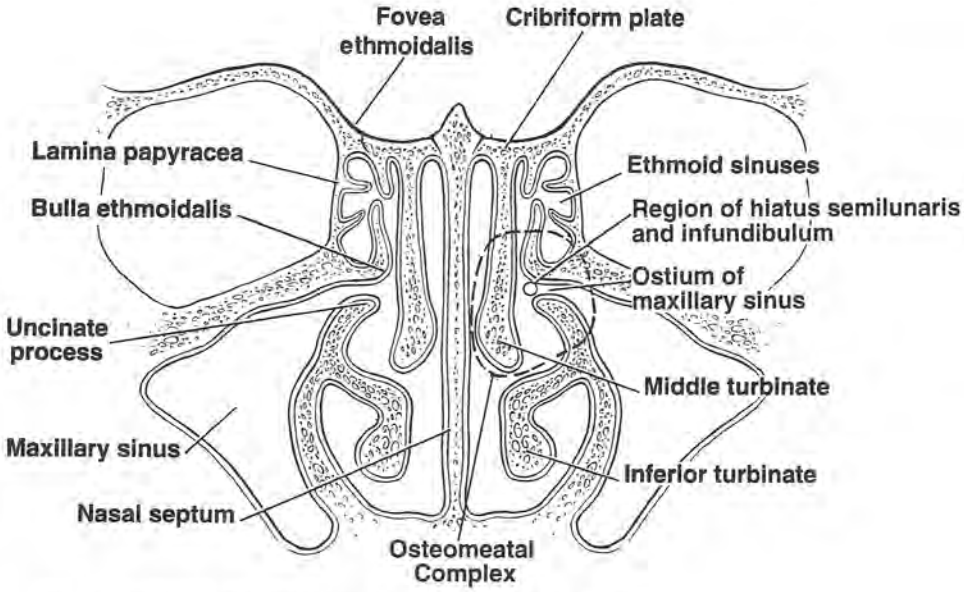

FIG. 5. A coronal section through the midvault of the nose.

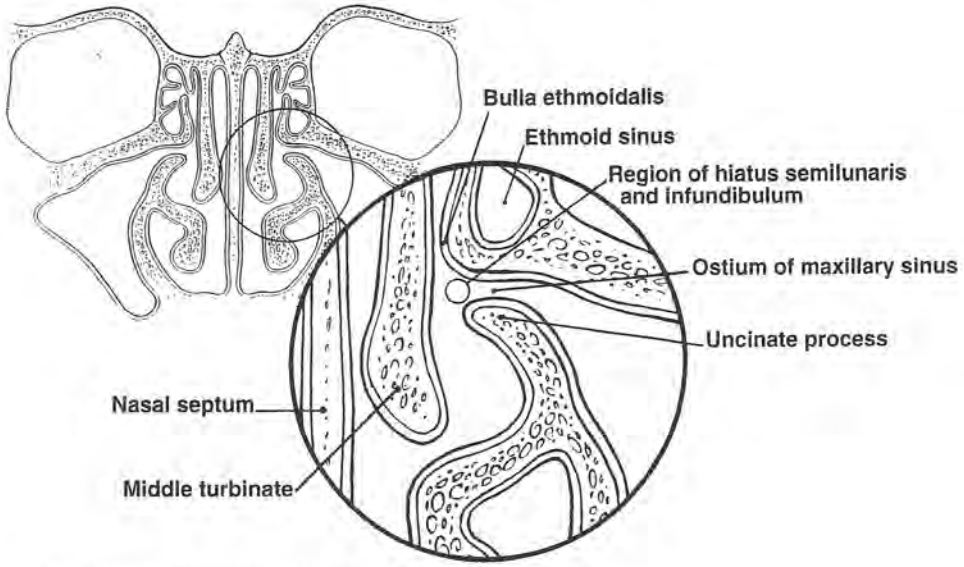

FIG. 6. The osteomeatal complex of the middle meatus.

aforementioned. Common sinus disease tends to emanate from this site; surgical intervention is aimed here as well.[7,8,12–16,19–22,25,26]

Along its entire length, the middle turbinate is suspended from the cribriform plate. It is further stabilized by a small wing of bone attached laterally (the basal lamella) that divides the anterior ethmoid cells from the posterior ethmoid cells. Lateral to the middle turbinate (within the anterior middle meatus) a small wall of bone called the *uncinate process* shields a curvilinear trough of space posterior to it (Fig. 7). This trough is the hiatus semilunaris and represents the portal of entry into the infundibulum. It is within the infundibulum that the frontonasal duct, the ethmoidal bulla, and the maxillary ostium all drain from their respective sinuses; it is the core of the osteomeatal unit.[7,8,12–16,19–22,25,26]

The superior turbinate is the highest projectile structure in the nose. It covers the superior meatus—the region into which the posterior ethmoid and sphenoid sinuses drain. This area is involved only during more extensive disease processes.[1]

Ultimately, the nasal cavity opens through bilateral posterior choanal portals into the nasopharynx (see Fig. 4). The superior border of

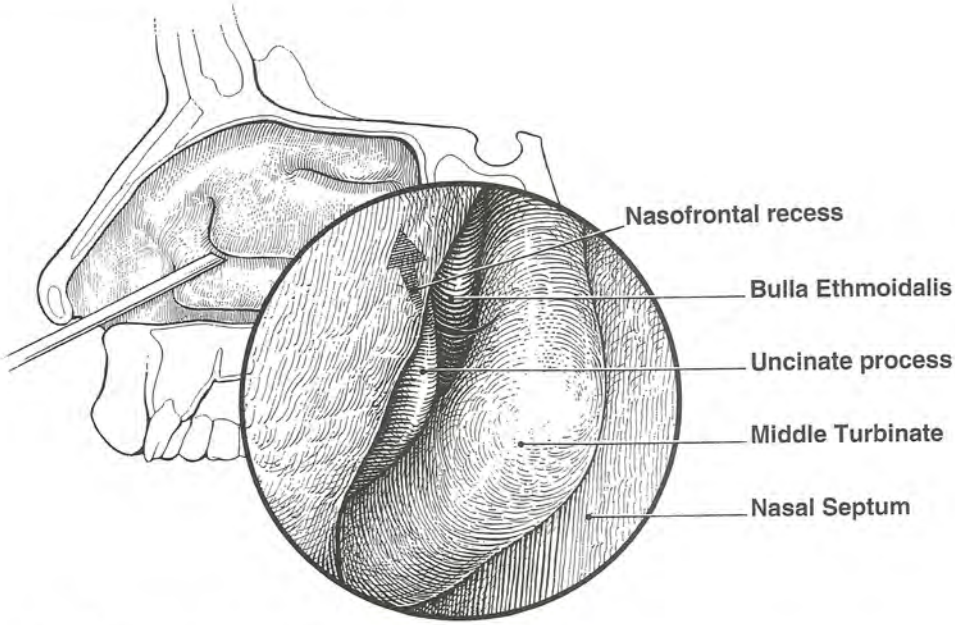

FIG. 7. Schematic view of the anterior middle meatus.

the nasopharynx is limited by the skull base and sphenoid bone; its inferior border is defined incompletely by the soft palate as the space declines posteroinferiorly into the oropharynx; its posterior wall contains the adenoid pad and adjacent recesses; and its lateral walls each house a eustachian tube orifice that is tightly bound by an elevation called the *torus tubaris*. A number of pathologic entities arise in the nasopharynx—most notably adenoid hypertrophy, mucosal inflammation along one or both eustachian tube orifices, and neoplastic disease.[10] All such processes are visible through the endoscope.

EQUIPMENT

Nasal endoscopes are manufactured by many different companies (e.g., Hopkins, Richards, Storz, and Wolf) that produce excellent-quality, cool-light, rigid telescopes with fiberoptic lens systems designed specifically for nasal examination (Fig. 8). The endoscopes needed for diagnostic purposes are available in two diameters and three angles. The diameters show various sized fields of view and are usually 2.7 or 4.0 mm. The angles (0, 30, and 70 degrees) reflect the divergence of view from the straightforward telescope (0 degrees). The endoscope for office use can be selected from any combination of these diameters and angles, although certain ones are more practical.

FIG. 8. A variety of commonly used nasal endoscopes.

The majority of adults should be inspected with 4.0-mm endoscopes. Advantages include the delivery of more light into the nose and an increase in field of view. The 2.7-mm endo-

scope is utilized in the adult patient in whom a significant nasal obstruction exists, in adults with smaller anatomic features, and in pediatric patients. It also should be used in tighter anatomic spaces within the nose. However, the 2.7-mm endoscope is fragile and consequently requires more maintenance.

Use of the 0-degree endoscope is the easiest to master because the practitioner does not have to compensate for a divergent visual angle. With increasingly angled endoscopes, the observer must adapt mentally to the altered direction of view as it relates to the remainder of the internal anatomy. Nevertheless, the 30-degree endoscope is the most applicable because the angle is still relatively acute and much of the nasal anatomy is positioned just superior to the nasal vestibule. Consequently, it allows for wide visualization of the lateral and medial nasal walls as it is rotated and advanced. The 70-degree endoscope is more specialized in its application and is best used to examine isolated areas of the medial or lateral wall, particularly the nasofrontal portal to the frontal sinus.

For office use, the required light source may be either a xenon or a halogen system (Fig. 9). The xenon light is usually a 300-W system and delivers superior illumination to any of the endoscopes, but it is expensive and bulky. The halogen light uses a 150-W light source. This is more economical and can be transferred easily between office viewing rooms or the hospital, but it really is not bright enough for intraoperative use. Both systems require a fiberoptic light cord of sufficient length.

Photographic documentation of the office examination is obtained with an adapted office camera unit. The camera provides permanent photographic recording of the examination and enhances patient education and academic teaching. However, the camera unit must be linked with the xenon light source.

Technique[2,9,10]

Nasal examination provides a rapid analysis not only of internal structural defects but also of mucosal conditions, whether they be normal, hyperemic, edematous, or friable. Every feature is of potential importance diagnostically.

The examination proceeds in a dual manner: first with a standard nasal speculum, then with a rigid, illuminated endoscope. The specular examination allows a quick survey of the vestibule and anterior nasal cavity. It should be done before and after topical anesthesia and vasoconstriction so that the acuteness or chronicity of mucosal pathology can be identified (an important distinction in many treatment algorithms). Chronically inflamed turbinates are far less likely to respond to the topical decongestant given during examination; in such cases, surgery may be required.

The nasal surgeon may use one of several commercially available cocaine solutions (e.g., 1%, 4%, 10%) for topical anesthesia and vasoconstriction. Other frequent substitutes are either easy to obtain or concoct, inexpensive, and less likely to be targeted for substance abuse. One such solution is a xylocaine 4%–phenylephrine 1% mixture combined as follows: 500 mg phenylephrine (neosynephrine) powder, 50 mg sodium bisulfite (preservative) powder, and 50 cc xylocaine 4% solution. Whatever the topical agent, it is either sprayed into the nasal cavity or inserted on cotton sponges along the floor and roof of each nostril. For full effect, the agent should be allowed to act approximately 5 to 7 minutes before further examination.



FIG. 9. Common lighting systems. (*Left*) Xenon system. (*Right*) Halogen system.

After the nasal mucosa is topically anesthetized and vasoconstricted and the second specular examination performed, diagnostic endoscopy begins. Before insertion, the tip of the endoscope must be washed to prevent fogging from exposure to the warm, humid air of the nasal cavity. Hot water, ethyl alcohol, Septisol, and No-Fog solution are common washes.

The patient is seated in an examination chair as the practitioner sits or stands to the right of the patient. Generally, the body of the endoscope is held in the right hand as the left hand guides the advancing tip (Fig. 10). The endoscope is placed first in the nasal vestibule and then advanced posteriorly along the floor of the nose beneath the inferior turbinate. This pass provides a view of the inferior meatus, the anterior and posterior aspects of the inferior turbinate, the septum, and the soft palate, eustachian tube orifices, and adenoid pad in the nasopharynx. Upon withdrawal of the endoscope, the sphenoethmoidal recess is evaluated, and previously examined areas are reinspected for missed pathology.

Distortion of view or blanching of mucosa suggests that the endoscope is too close or even embedded in tissue. Partial withdrawal of the instrument usually alleviates this condition; endoscopic examination is best done with the tip at a slight distance from the area of interest. This increases perspective and field of view.

The second pass of the endoscope is directed superior to the inferior turbinate but below the middle turbinate. Here, the examiner must focus specifically on the middle turbinate and the osteomeatal complex region. This may require a gentle medial retraction of the middle turbinate with the endoscope so that its tip can be insinuated into the middle meatus. (A 2.7-mm endoscope may be more useful in this space.) The frontoethmoidal recess and nasofrontal duct region also should be evaluated at this time. As the endoscope is advanced further, the posterior ethmoidal area is inspected. Once again, methodical withdrawal of the endoscope allows for a reassessment of the examined areas.

FIG. 10. Diagnostic nasal endoscopy in progress.

Adjunctive views may be gained with the additional pass of a 70-degree endoscope. The nasofrontal region, concealed in the anterosuperior crevice of the middle meatus, is most appropriately accessed with this more angulated endoscope (see Fig. 7). Also, if on occasion an accessory ostium exists beneath the middle turbinate, the 70-degree endoscope can provide visualization of the entire maxillary antrum.

As a general rule, all aspects of the nasal examination should be performed with delicacy and finesse. Despite proper anesthetic preparation, the nose is an exquisitely sensitive organ and prone to traumatic injury when handled roughly; the endoscope should never be forced into a desired position. All in all, although involved with several details, the entire nasal assessment is expedient, straightforward, and rewarding once the steps are carefully learned and practiced.

DISCUSSION

Diagnostic nasal endoscopy has advanced the surgeon's ability to identify internal nasal abnormalities, and its role continues to grow. It is to be distinguished from endoscopically assisted intranasal surgery, which requires in-depth training, cadaveric practice, and initial intraoperative supervision by an experienced endoscopist. The potential hazards of such surgery are multiple and profound. They relate to the proximity of the cranial and orbital cavities and have included significant hemorrhage, cerebrospinal fluid leak, and blindness.[23] Indeed, even the practitioner interested strictly in the diagnostic aspect of nasal endoscopy would benefit from hands-on cadaveric practice and guidance from a trained endoscopist.

Caveats notwithstanding, endoscopy offers a clear, comprehensive view of internal nasal anatomy. In so doing, it augments the plastic surgeon's understanding of airway complaints. Whether the clinician later elects to refer complicated problems to a rhinologic specialist, the broad diagnostic potential provided by this technology optimizes patient care from the outset.

SUMMARY

Endoscopy has gained wide popularity due to its protean applications and efficacy in many surgical specialties. Diagnosis and treatment of nasal diseases have advanced in the process. However, proper training in nasal endoscopy is critical. The nose is an intricate organ fundamentally and has such proximity to other vital structures that procedural miscues can cause serious complications.

This paper traces the historical development of nasal endoscopy, explains its rationale, reviews anatomic and diagnostic issues, and describes the selection of equipment and correct application of technique, emphasizing the potential for advanced diagnostic skills.

Rod J. Rohrich, M.D.
Department of Plastic Surgery
University of Texas, Southwestern Medical Center
5323 Harry Hines Boulevard
Dallas, Texas 75235-9132

ACKNOWLEDGMENTS

We wish to thank Stephen T. Brown, M.A., for his patience and skill in rendering the illustrations and Debby Noble for her technical support.

REFERENCES

1. Anand, V. K., and Panje, W. R. *Practical Endoscopic Sinus Surgery.* New York: McGraw-Hill, 1993.
2. Bolger, W. E., and Kennedy, D. W. Nasal endoscopy in the outpatient clinic. *Otolaryngol. Clin. North Am.* 25: 791, 1992.
3. el-Silimy, O. Endonasal endoscopy and posterior epistaxis. *Rhinology* 31: 119, 1993.
4. Fisher, E. W., and Croft, C. B. Antroscopy in outpatient management: A prospective study. *Clin. Otolaryngol.* 16: 212, 1991.
5. Gustafson, R. O., and Kern, E. B. Office endoscopy: When, why, what, and how. *Otolaryngol. Clin. North Am.* 22: 683, 1989.
6. Kaluscar, S. K., and Patil, N. P. The role of out-patient nasal endoscopy in the evaluation of chronic sinus disease. *Clin. Otolaryngol.* 17: 193, 1992.
7. Kennedy, D. W., Zinreich, S. J., Rosenbaum, A. E., and Johns, M. E. Functional endoscopic sinus surgery: Theory and diagnostic evaluation. *Arch. Otolaryngol.* 111: 576, 1985.
8. Kennedy, D. W. Functional endoscopic sinus surgery: Technique. *Arch. Otolaryngol.* 111: 643, 1985.
9. Levine, H. L. The office diagnosis of nasal and sinus disorders using rigid nasal endoscopy. *Otolaryngol. Head Neck Surg.* 102: 370, 1990.
10. Lund, V. J. Office evaluation of nasal obstruction. *Otolaryngol. Clin. North Am.* 25: 803, 1992.
11. Maltz, M. New instrument: The sinuscope. *Laryngoscope* 35: 805, 1925.
12. Messerklinger, W. On the drainage of the normal frontal sinus of man. *Acta Otolaryngol.* 63: 176, 1967.
13. Messerklinger, W. Uber die Drainage der menschlichen Nasennebenhohlen unter normalen und pathologischen Bedingungen: II. Die Stirnhohle und ihr Ausfuhrungssystem. *Monatschr. Ohrenheilhk.* 101: 313, 1967.
14. Messerklinger, W. Endoscopy of the Nose. Baltimore: Urban & Schwarzenberg, 1978.
15. Messerklinger, W. Uber den Recessus frontalis und seine Klinik. *Laryngol. Rhinol. Otol.* 61: 217, 1982.
16. Messerklinger, W. Endoskopische Diagnose und Chirurgie der Rezidivierenden Sinusitis. In Z. Krajina (Ed.), *Advances in Nose and Sinus Surgery.* Zagreb: Zagreb University Press, 1985.
17. Pownell, P. H., and Rohrich, R. J. Endoscopic-assisted partial inferior turbinate resection in the management of nasal airway obstruction. *Perspect. Plast. Surg.* 8: 92, 1994.
18. Pownell, P. H., and Rohrich, R. J. Nasal Airway Surgery. In J. Bostwick, F. Eaves, and F. Nahai (Eds.), *Endoscopic Plastic Surgery.* St. Louis: Quality Medical Publishing, 1994. Pp. 319–338.
19. Rice, D. H., and Schaefer, S. D. *Endoscopic Paranasal Sinus Surgery,* 2d Ed. New York: Raven Press, 1993.
20. Schaefer, S. D., Manning, S. C., and Close, L. G. Endoscopic paranasal sinus surgery: Indications and considerations. *Laryngoscope* 99: 1, 1989.
21. Stammberger, H. Endoscopic endonasal surgery: Concepts in treatment of recurring rhinosinusitis: I. Anatomic and pathophysiologic considerations. *Otolaryngol. Head Neck Surg.* 94: 143, 1986.
22. Stammberger, H. Endoscopic endonasal surgery: Concepts in treatment of recurring rhinosinusitis: II. Surgical technique. *Otolaryngol. Head Neck Surg.* 94: 147, 1986.
23. Stankiewicz, J. A. Complications of endoscopic intranasal ethmoidectomy. *Laryngoscope* 97: 1270, 1987.
24. Vining, E. M., Yanagisawa, K., and Yanagisawa, E. The importance of preoperative nasal endoscopy in patients with sinonasal disease. *Laryngoscope* 103: 512, 1993.
25. Wigand, M. E., Steiner, W., and Jaumann, M. P. Endonasal sinus surgery with endoscopical control: From radical operation to rehabilitation of the mucosa. *Endoscopy* 10: 255, 1978.
26. Wigand, M. E. Transnasal ethmoidectomy under endoscopical control. *Rhinology* 19: 7, 1981.
27. Pashley, N. R. T. Congenital Anomalies of the Nose. In C. W. Cummings, J. M. Fredrickson, L. A. Harker, C. J. Krause, and D. E. Schuller (Eds.), *Otolaryngology–Head and Neck Surgery.* St. Louis: Mosby, 1986. Pp. 573–584.
28. Hill, J. H. Infections. In C. W. Cummings, J. M. Fredrickson, L. A. Harker, C. J. Krause, and D. E. Schuller (Eds.), *Otolaryngology–Head and Neck Surgery.* St. Louis: Mosby, 1986. Pp. 585–595.
29. McDonald, T. J. Manifestations of Systemic Disease. In C. W. Cummings, J. M. Fredrickson, L. A. Harker, C. J. Krause, and D. E. Schuller (Eds.), *Otolaryngology–Head and Neck Surgery.* St. Louis: Mosby, 1986. Pp. 597–609.
30. Maceri, D. R., and Mathog, R. H. Trauma. In C. W. Cummings, J. M. Fredrickson, L. A. Harker, C. J. Krause, and D. E. Schuller (Eds.), *Otolaryngology–Head and Neck Surgery.* St. Louis: Mosby, 1986. Pp. 611–637.
31. DeSanto, L. W. Neoplasms. In C. W. Cummings, J. M. Fredrickson, L. A. Harker, C. J. Krause, and D. E. Schuller (Eds.), *Otolaryngology–Head and Neck Surgery.* St. Louis: Mosby, 1986. Pp. 639–650.