THE AMERICAN SOCIETY FOR AESTHETIC PLASTIC SURGERY

AESTHETIC SURGERY JOURNAL



JANUARY/FEBRUARY 1998

Postrhinoplasty Airway Problems • Face Lift Complications

Histologic Effects of Chemabrasion, Dermabrasion, and Laserbrasion

ISSN 1090-820X

A Comparison of the Histologic Effects of Chemabrasion, Dermabrasion, and Laserbrasion in the Minipig

John J. Minoli, MD; and Fritz E. Barton, Jr., MD

This study was designed to evaluate the short- and long-term histologic consequences of some common skin resurfacing methods. Grids were tattooed on the sides of a Yucatan minipig, the standard model for human skin experiments. Each grid cell was treated with one of the following: Jessner's solution, lactic acid, glycolic acid, trichloroacetic acid with and without Retin-A® pretreatment, phenol, dermabrasion, or carbon dioxide laser (Sharplan SilkTouch® or Coherent UltraPulse®). All treatments were given at the usual doses or strengths recommended for human skin. Each treatment method was represented by two grid cells on either side. Biopsy specimens were obtained from each area immediately after treatment and at 1 week, 1 month, and 3 months. The histologic sections were read by an experienced dermatopathologist. The superficial peeling agents (glycolic acid, lactic acid, and Jessner's solution) barely penetrated the epidermis. Wound depth from dermabrasion and laserbrasion could be traced to the papillary-reticular junction of the dermis in the early sections, but by 3 months the skin in these areas had resumed its normal architecture. In contrast, phenol and trichloroacetic acid produced changes to the upper reticular dermis, and these findings persisted for the duration of the observation period. The effects of treatment with the carbon dioxide lasers had dissipated by 3 months. Higher levels of laser energy are apparently needed to induce resurfacing in this model.

Resurfacing techniques date back several millennia. Although time-honored, chemabrasion and dermabrasion have inherent limitations.[1-9] Superficial peeling preparations such as glycolic acid, lactic acid, Jessner's solution, and tretinoin are incapable of eliminating deep wrinkles; medium-depth phenol peeling solutions have melanotoxic potential; and deep peeling solutions of ≥50% trichloroacetic acid (TCA) are likely to produce hypertrophic scarring.[3-9] Mechanical dermabrasion is operator dependent and typically has the highest rate of blood loss.[1,2,10] Short-pulsed, high-energy CO_2 lasers that vaporize tissue cleanly and minimize thermal damage have become very popular in the last few years.[10-14] Comparative animal studies and early histologic studies in human beings show similar tissue effects of CO_2 laser and medium-depth peeling agents,[11] but the sampling periods have been short.[13] We investigated the histologic effects of the CO_2 laser compared with common chemabrasive and dermabrasive techniques for skin rejuvenation. Our model was the Yucatan miniature pig, whose skin closely resembles human skin.[15,16] We

From the Department of Plastic Surgery, the University of Texas Southwestern Medical Center, Dallas, TX.

Accepted for publication Dec. 23, 1997.

Reprint requests: Fritz E. Barton, Jr., MD, 411 N. Washington, no. 6000, Dallas, TX 75246.

Copyright © 1998 by the American Society for Aesthetic Plastic Surgery, Inc.

190-820X/98/$5.00 + 0

70/1/88377

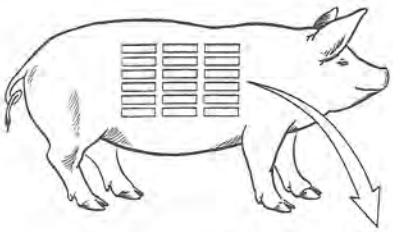



Figure 1. *Topographic pattern for application of treatment modalities, duplicated bilaterally.*

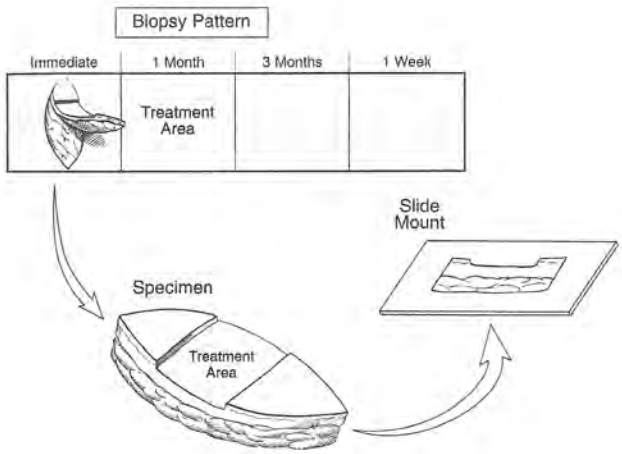

Figure 2. *Method of specimen handling from biopsy to slide mounting.*

chose a 3-month period of observation to monitor the initial inflammatory and proliferative healing responses into the maturation phase.[9,17]

Material and Methods

A 6-month-old, 30 kg, nonphotoaged, female Yucatan minipig was our test subject. The pig was kept according to guidelines for the care and maintenance of experimental animals established by the Food and Drug Administration and our institutional review board. At the beginning of each biopsy session, the pig was given general anesthetic, and afterward the wounds were dressed with Telfa® and Flexinet®. Postinterventional analgesia was a single intramuscular injection of buprenorphine 0.57 mg. Daily intramuscular injections of penicillin G 300,000 units were given prophylactically.

Grids were tattooed on the animal's sides, each consisting of 18 rectangles 1 cm wide by 12 cm long (Figure 1). A dif-

Table 1
Treatments

Glycolic acid 50%	Cotton-tipped application; washed with water after 5 minutes
Lactic acid 70%	Cotton-tipped application; washed with water after 5 minutes
Jessner's solution*	Cotton-tipped application; light tissue frosting was end point
TCA 35%	Cotton-tipped application; moderate tissue frosting was end point
TCA 35% + Retin-A®	Cotton-tipped application; moderate tissue frosting was end point
Phenol (Baker's formula)†	Cotton-tipped application; moderate tissue frosting was end point
Dermabrasion	Metal wire-brush; punctate dermal bleeding was end point
CO_2 laser‡	Water-dampened gauze wipe then dry gauze wipe after each pass
CO_2 laser§	Water-dampened gauze wipe then dry gauze wipe after each pass

*14 gm salicylic acid, 14 gm resorcinol, 14 ml lactic acid 85%, ethanol 95% added for 100 ml total volume.[7]
†3 ml liquid phenol, 2 ml tap water, 8 drops liquid soap, 3 drops croton oil.[9]
‡Sharplan SilkTouch® Surgilase at 18 W, 6 mm scan diameter with 20% overlap—two passes.
§Coherent UltraPulse® at 250 mJ, 2.25 mm scan diameter with 30% overlap—three passes.



Figure 3. *Mean depth of penetration of each treatment modality immediately after application.*

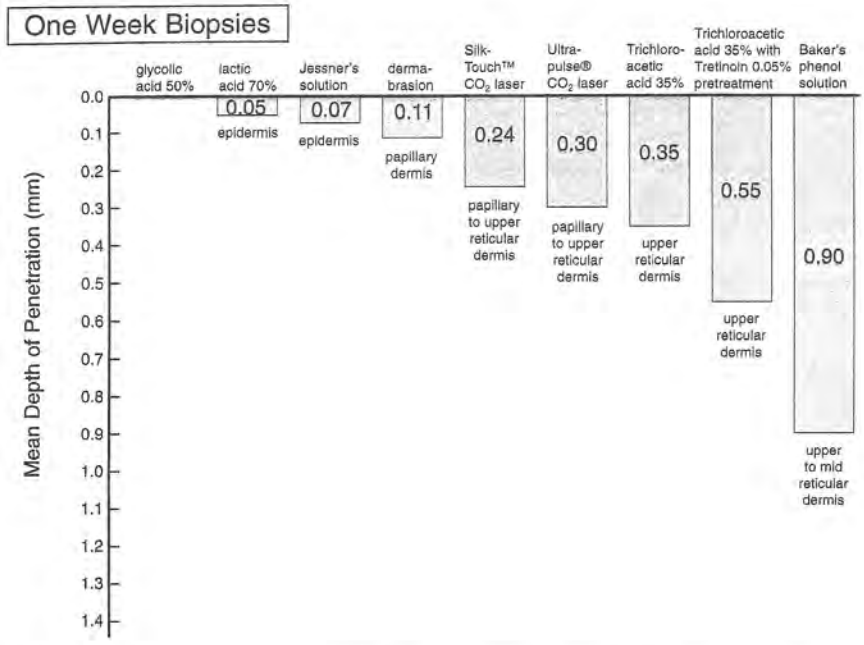

Figure 4. *Mean depth of penetration of each treatment modality 1 week after application.*

ferent treatment method was designated for every nine grid cells, taking care to reverse the pattern so that each method was equally represented on dorsal and ventral sites. Tretinoin 0.05% cream was rubbed on half of the TCA grids daily for 2 weeks before treatment was begun. All treatments were given the same day after degreasing the areas with acetone. These treatments are listed in Table 1.

Biopsy specimens were obtained immediately after treatment and at 1 week, 1 month, and 3 months. The biopsy cuts were taken through full-thickness skin and oriented vertically to include treated and nontreated skin in each excision (Figure 2). Control biopsy specimens were obtained from the dorsal and ventral flank on either side. All biopsy sites were closed with 2-0 nylon skin sutures. A

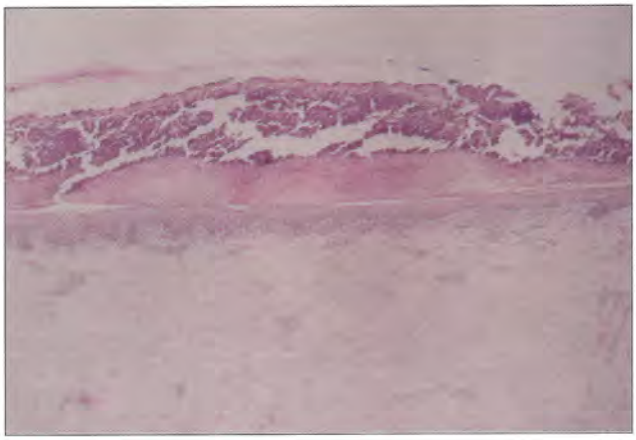

Figure 5. *Cross-section of pig skin 1 week after dermabrasion. (H&E stain; original magnification × 40.)*

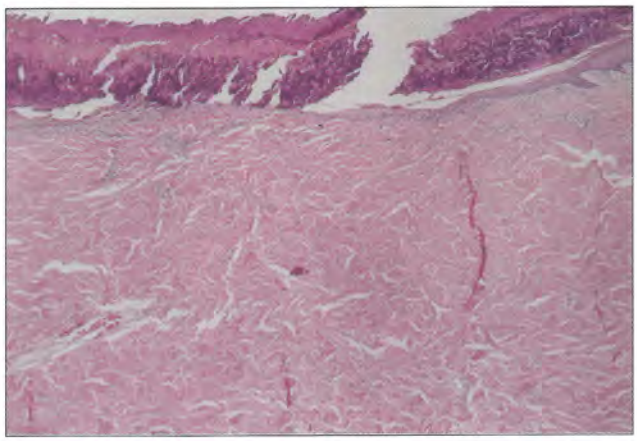

Figure 6. *Cross-section of pig skin 1 week after laserbrasion with the Coherent UltraPulse® laser. (H&E stain; original magnification × 40.)*

total of 110 biopsy specimens were collected over the 3-month study period. Histologic sections were prepared with hematoxylin-eosin (H&E) and Movat stains. A board-certified dermatopathologist, blinded to the study protocol, analyzed all specimens according to the following criteria:

- depth of lesion (in micrometers)
- inflammatory response (grades 1 to 4)
- epidermal changes (e.g., thickened epithelium, cellular proliferation)
- dermal changes (mild, moderate, or severe, with special reference to collagen and elastin)

Results

Immediate

Mechanical dermabrasion penetrated the epidermis, which

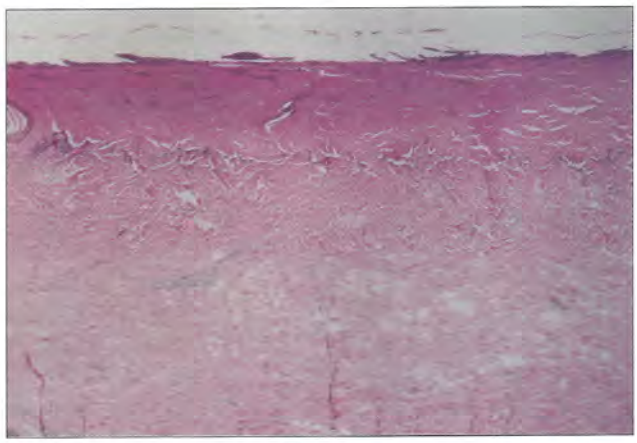

Figure 7. *Cross-section of pig skin 1 week after chemabrasion with trichloroacetic acid 35%. (H&E stain; original magnification × 40.)*

was thoroughly disrupted. Both lasers caused upper dermal necrosis, the SilkTouch® involving the papillary layer and the UltraPulse® the upper reticular layer of dermis. Other treatment methods produced no discernible effects (Figure 3).

One Week

Most specimens bore signs of change except the glycolic acid group, which appeared to be unaffected (Figure 4). Lactic acid and Jessner's grid cells showed evidence of partial epidermal necrosis. The dermabrasion specimens were notable for vast epidermal necrosis and beginning reepithelialization. The papillary dermis was diffusely involved, showing wavy and disorganized collagen architecture, regional absence of elastin, and mild proliferation of fibroblasts and granulation tissue (Figure 5).

Laser treatment induced epidermal necrosis and reepithelialization, as well as a moderate inflammatory reaction. Numerous fibroblasts and abundant granulation tissues were seen in the papillary and upper reticular dermis. Collagen was coagulated, horizontally compacted, and occasionally disorganized, and elastin was absent (Figure 6). The histologic changes produced by phenol and by TCA with and without Retin-A® were similar to those of the lasers, but deeper (Figure 7). Phenol-induced effects were seen in the midreticular layer of dermis. TCA penetrated well into the upper reticular dermis, and pretreatment with tretinoin seemed to facilitate tissue encroachment.

One Month

The histologic sections of biopsy specimens obtained 1 month after treatment showed normal skin for specimens

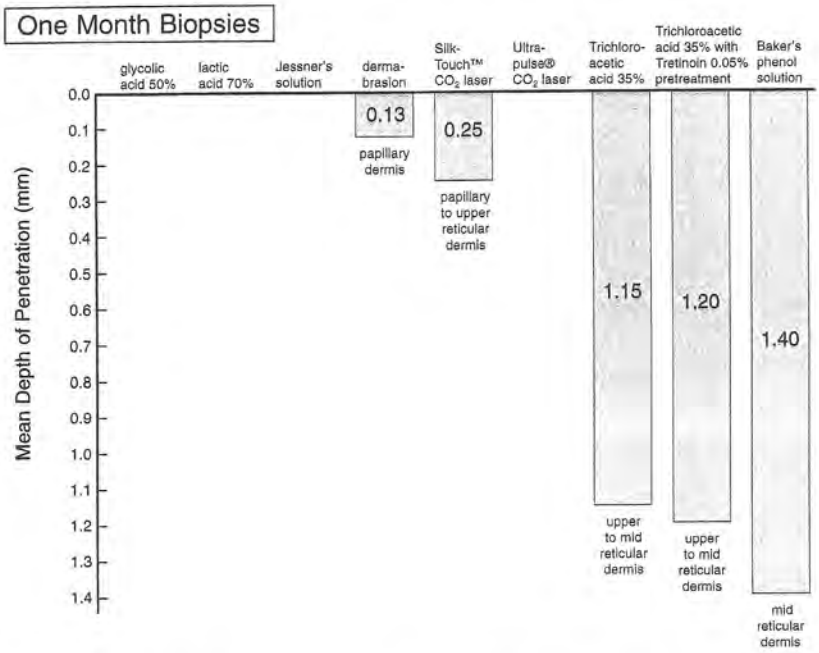

Figure 8. *Mean depth of penetration of each treatment modality at 1 month.*

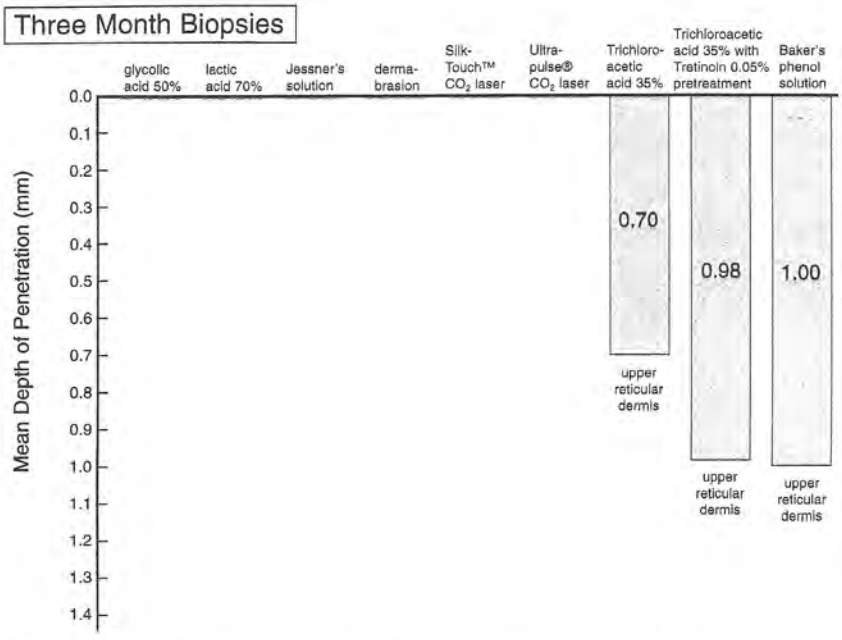

Figure 9. *Mean depth of penetration of each treatment modality at 3 months.*

treated with glycolic acid, lactic acid, and Jessner's solution (Figure 8). The dermabrasion specimens exhibited normal collagen deposition, an absence of elastin, and mild fibroblastic proliferation to the papillary dermis. SilkTouch® laserbrasion sections showed a disorganized collagen layer, normal elastin, and fibroblastic invasion to the upper reticular dermis. Specimens treated with phenol and trichloroacetic acid with or without pretreatment with Retin-A® showed various collagen patterns, at times wavy and disorganized and other times horizontally compacted.

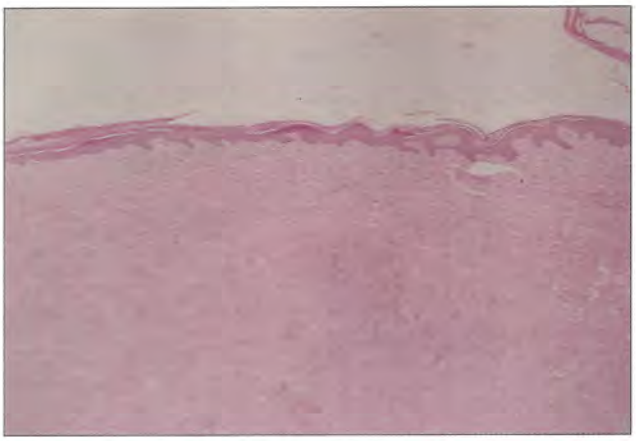

Figure 10. *Cross-section of pig skin 3 months after dermabrasion. (H&E stain; original magnification × 40.)*

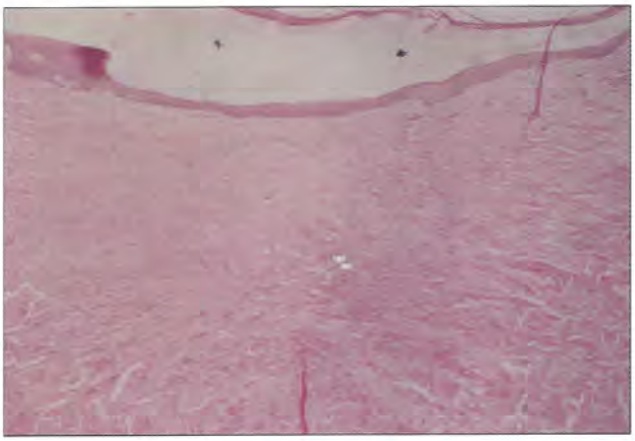

Figure 12. *Cross-section of pig skin 3 months after chemabrasion with TCA 35%. (H&E stain; original magnification × 40.)*

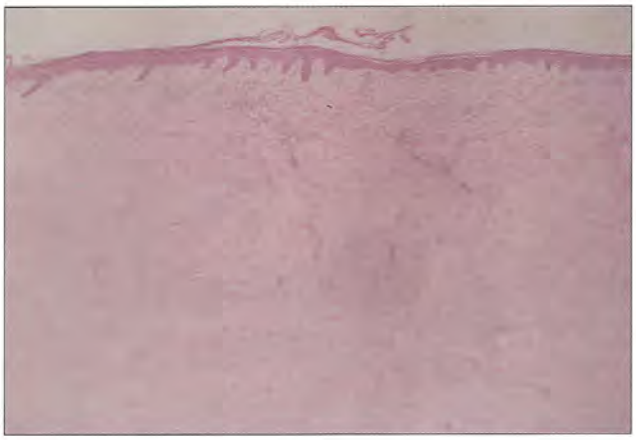

Figure 11. *Cross-section of pig skin 3 months after laserbrasion with the Coherent UltraPulse® laser. (H&E stain; original magnification × 40.)*

Elastin was absent, and fibroblasts and granulation tissue showed moderate to severe proliferation. The level of penetration seemed progressively deeper, from superficial for TCA, upper reticular dermis for TCA with Retin-A®, and midreticular dermis for phenol.

Three Months

By the last observation period, only the TCA and phenol groups showed histologic changes consisting of residual fibroblastic proliferation and densely compacted, horizontally oriented collagen amid a hyaline matrix devoid of elastin. Granulation tissue was evident in the upper reticular dermis (Figures 9 to 12). The other treatment groups showed essentially normal skin, with slightly increased dermal thickness across the board.[3,7,9] Once again a progressive depth of penetration was noted from TCA to phenol, but this time only into the upper reticular dermis. A summary of these histologic findings is presented in Table 2.

Examination of the control biopsy specimens revealed that full-thickness dorsal skin tended to be thicker (mean 2.8 mm) than ventral skin (mean 2.5 mm) in our model. The histologic effects of treatment went deeper in the thinner ventral skin of our animal (0.955 ± 0.566 mm) than on the dorsum (0.550 ± 0.452 mm).

Discussion

This study was designed to identify specific short- and long-term microscopic changes produced by common skin resurfacing techniques. Many of our results agreed with those of other investigators.[3,7,9] Light peeling agents (glycolic acid, lactic acid, Jessner's solution) confined their effects primarily to the epidermis. Intermediate peeling agents (TCA with and without Retin-A®, phenol) caused permanent compaction, orderly reorientation, and hyalinization of collagen, as well as a decrease in elastin. The effects of dermabrasion and laserbrasion were less striking. Even though these methods produced short-term dermal changes (disorganized, coagulated, and compacted collagen; diminished elastin), by 3 months the skin had reverted to normal. Several studies have also shown that dermabrasion does not induce the profound histologic response seen after medium-depth chemabrasion.[18-20] Dermabrasion elicits neocollagen synthesis, but late biopsy specimens showed a return to the pretreatment skin architecture.[21]

Our pig's tough truncal skin probably muted the effects of the lasers, which were set for human facial skin. Most clinicians rely on the appearance of a faint yellow hue to signal

Table 2

Summary of Histologic Findings by Treatment Method

Treatment	Epidermis	Collagen	Elastin	Depth of penetration
Glycolic acid 50%	No change	No change	No change	None measured
Lactic acid 70%	Minimal necrosis first week; no change at 1 month	No change	No change	To epidermis at 1 week, none at 1 or 3 months
Jessner's solution	Minimal necrosis first week; no change at 1 and 3 months	No change	No change	To epidermis at 1 week, none at 1 or 3 months
Dermabrasion	Reepithelialization after 1 week	Wavy and disorganized at 1 week; normal at 1 and 3 months	Absent at 1 week and 1 month; normal at 3 months	To epidermis immediately; to papillary dermis at 1 week and 1 month; none at 3 months
SilkTouch® laser	Immediate necrosis; reepithelialization after 1 week	Compact and coagulated at 1 week; disorganized at 1 month; normal at 3 months	Absent at 1 week; normal at 1 month	Immediate to papillary dermis; papillary to upper reticular dermis at 1 week and 1 month; none at 3 months
UltraPulse® laser	Immediate necrosis; reepithelialization after 1 week	Compact, coagulated, and disorganized at 1 week, normal at 1 and 3 months	Absent at 1 week; normal at 1 and 3 months	Papillary to upper reticular dermis immediately and at 1 week; none at 1 and 3 months
TCA	Reepithelialization after 1 week	Compact, coagulated, and disorganized at 1 week and 1 month; hyalinization at 3 months	Absent at 1 week, 1 month, and 3 months	Upper reticular dermis at 1 week; to upper/midreticular dermis at 1 month; to upper reticular dermis at 3 months
TCA + Retin-A®	Reepithelialization after 1 week; hyperkeratosis at 3 months	Compact, coagulated, and wavy/disorganized at 1 week and 1 month; hyalinization at 3 months	Diminished to absent at 1 week, 1 month, and 3 months	Upper/midreticular dermis at 1 month; upper reticular dermis at 1 week and 3 months
Phenol	Reepithelialization after 1 week; hyperkeratosis at 3 months	Compact, coagulated, and wavy/disorganized at 1 week and 1 month; hyalinization at 3 months	Diminished to absent at 1 week, 1 month, and 3 months	Upper/midreticular dermis at 1 week and 1 month; upper reticular dermis at 3 months

the end point of treatment,[22] but we adhered to our protocol, which called for predetermined energy levels and number of passes. The UltraPulse® parameters used in this study—three passes at 250 mJ with a 2.25 mm spot and 30% overlap—were similar to the laser settings that barely penetrated a Yorkshire pig dermis in a study by Fitzpatrick et al.[13] These authors determined that UltraPulse® energy of 350 to 450 mJ in two to three passes was required to breach the upper reticular dermis and increase dermal fibrosis.[13] When we did use a clinical sign—tissue frosting—to indicate the end point of treatment with TCA and phenol, the resultant histologic changes reached a deeper level and were longer lasting than for other resurfacing methods. Skin primed for 2 weeks with tretinoin 0.05%

cream appeared less cornified and allowed deeper penetration of the agent than skin that had not been pretreated with Retin-A®.

The resurfacing CO_2 laser delivers energy in short pulses that limit tissue dwell-time to less than 1 msec. The targeted tissue is accurately vaporized, whereas thermal damage to surrounding structures is kept to a minimum.[14] Because the short-pulsed CO_2 laser is relatively new, no studies of its long-term effects on skin have been published to date. Clinically, the laser seems to shrink human epidermal and dermal tissues. Fitzpatrick et al.[12] describe three tissue layers after exposure to the CO_2 laser: a vaporized zone, a necrotic zone, and a zone of reversible thermal damage.[12] Within this last zone collagen shrinkage is believed to occur, and this is presumably the mechanism responsible for the disappearance of fine wrinkles.[12]

We chose a Yucatan miniature pig as our animal model because the skin of this breed is said to be similar to human skin in gross and microscopic architecture and absorptive properties.[15,16] Nevertheless, our pig's hide was unquestionably tougher overall and had a considerably deeper stratum corneum than human skin. We believe that the thicker porcine epidermis limited penetration of the skin resurfacing agents and blunted their histologic effects. The apparent lack of lasting results seen after treatment with the CO_2 laser is attributed to insufficient doses for this model and is not meant to represent the clinical situation.

Conclusion

We compared depth of penetration of several nonsurgical methods of skin rejuvenation in a minipig model. Biopsy specimens were obtained immediately after treatment and at 1 week, 1 month, and 3 months. Only those areas treated with phenol or TCA showed any discernible histologic changes at 3 months. This finding corresponded with deeper skin penetration by those agents. ■

This study would have been impossible without Max Solano, MD, dermatopathologist. We are greatly indebted to him for his cheerful cooperation and tireless examination of our tissue slides. We also thank Grace Darling, ELS, for her editorial assistance in the preparation of this manuscript.

References

1. Alt TH. Facial dermabrasion: advantages of the diamond fraise technique. J Dermatol Surg Oncol 1987;13:618-24.
2. Ayres S, Wilson JW, Luikart R. Dermal changes following abrasion. Arch Dermatol 1959;79:553-7.
3. Ayres S. Dermal changes following application of chemical cauterants to aging skin: superficial chemosurgery. Arch Dermatol 1960;82:578-83.
4. Baker TJ, Gordon HL, Mosienko P, Seckinger DL. Long-term histological study of skin after chemical face peeling. Plast Reconstr Surg 1974;53:522-5.
5. Green LJ, McCormick A, Weinstein GD. Photoaging and the skin. The effects of tretinoin. Dermatol Clin 1993;11:97-105.
6. Roenigk RK, Brodland DG. A primer of facial chemical peel. Dermatol Clin 1993;11:349-59.
7. Rubin MG. Trichloroacetic acid and other non-phenol peels. Clin Plast Surg 1992;19:525-36.
8. Stegman SJ. A comparative histologic study of the effects of three peeling agents and dermabrasion on normal and sun-damaged skin. Aesthet Plast Surg 1982;6:123-35.
9. Stuzin JM, Baker TJ, Gordon HL. Treatment of photoaging: facial chemical peeling (phenol and trichloroacetic acid) and dermabrasion. Clin Plast Surg 1993;20:9-25.
10. Hruza GJ, Dover JS. Laser skin resurfacing. Arch Dermatol 1996;132:451-5.
11. Cotton J, Hood AF, Gonin R, Beesen WH, Hanke CW. Histologic evaluation of preauricular and postauricular human skin after high-energy, short-pulse carbon dioxide laser. Arch Dermatol 1996;132:425-8.
12. Fitzpatrick RE, Goldman MP, Satur NM, Tope WD. Pulsed carbon dioxide laser resurfacing of photo-aged facial skin. Arch Dermatol 1996;132:395-402.
13. Fitzpatrick RE, Tope WD, Goldman MP, Satur NM. Pulsed carbon dioxide laser, trichloroacetic acid, Baker-Gordon phenol, and dermabrasion: a comparative clinical and histologic study of cutaneous resurfacing in a porcine model. Arch Dermatol 1996;132:469-71.
14. Green HA, Domankevitz Y, Nishioka NS. Pulsed carbon dioxide laser ablation of burned skin: in vitro and in vivo analysis. Lasers Surg Med 1990;10:476-84.
15. Kurihara-Bergstrom T, Woodworth M, Feisullin S, Beall P. Characterization of the Yucatan miniature pig skin and small intestine for pharmaceutical applications. Lab Anim Sci 1986;36:396-9.
16. Bloom W, Fawcett DW. A textbook of histology. 10th ed. Philadelphia: WB Saunders; 1975:563-97.
17. Robinson JB, Friedman RM. Wound healing and closure. Selected Readings in Plastic Surgery 1995;8:1-36.
18. Baker TJ, Gordon HL. Chemical face peeling and dermabrasion. Surg Clin North Am 1971;51:387-401.
19. Behin F, Feuerstein SS, Marovitz WF. Comparative histological study of mini pig skin after chemical peel and dermabrasion. Arch Otolaryngol 1977;103:271-7.
20. Baker TJ, Stuzin JM. Chemical peeling and dermabrasion. In: McCarthy JG, ed. Plastic surgery. Philadelphia: WB Saunders; 1990:748-86.
21. Benedetto AV, Griffin TD, Benedetto EA, Humeniuk HM. Dermabrasion: therapy and prophylaxis of the photoaged face. J Am Acad Dermatol 1992;27:439-47.
22. Burns AJ. Laser resurfacing. Presented at: the Cutaneous Laser Surgery Symposium; June 14-16, 1996; Dallas, TX.